

Use of the 21 Fr. Princess Bipolar Resectoscope for Hysteroscopic Resection of Submucosal Fibroids

Techniques by DR. KEITH ISAACSON

History

Patient is a 33 year old G2P0 female with a history of increasingly heavy and crampy periods. She and her husband have been attempting to conceive for the past 18 months and have suffered from two first trimester miscarriages. Their fertility evaluation has included a normal semen analysis, a normal hysterosalpingogram that demonstrated bilateral patent tubes with no intrauterine defect, and a normal day three hormonal profile. Her past medical history is unremarkable. She has had no prior surgeries and her family history is significant for uterine fibroids in both her mother and maternal aunt. She has regular cycles lasting 4 to 5 days with clots. There is no history of anemia. She is on no medications other than prenatal vitamins daily.

Procedure

During patient's initial office visit a gynecologic exam was completed and was unremarkable. Her uterus was anteverted, normal size and mobile. No adnexal masses were palpated. A vaginal probe ultrasound was performed and both ovaries appeared normal. There was a 2.5 cm myoma noted near the uterine cavity. A 3D ultrasound was obtained and the fibroid appeared to be 60% in the cavity and 40% intramural consistent with a Type I submucous myoma. A diagnostic office hysteroscopy was performed with a 3 mm rigid hysteroscope and normal saline for distention using a vaginoscopic approach. The findings were consistent with the 3D ultrasound. Both tubal ostia were visualized and confirmed during the office hysteroscopy with an anterior fundal Type I, 2-3 cm myoma protruding into the uterine cavity. Patient was scheduled for an operative hysteroscopic myomectomy.

Patient was taken to the operating room and given total intravenous anesthesia (TIVA). Her vagina was prepped with betadine and the cervix was dilated using a 21 Fr dilator. Normal saline was used for distention and the inflow and outflow was continuously monitored using a weighted monitoring system. A hysteroscopic morcellator was used to shave the myoma as much as possible to include the intramural portion of the fibroid (see image 1). Because the patient desires fertility, it is important to remove 100% of the myoma so that there will be no re-growth or protrusion of the remaining intramural portion into the uterine cavity that could lead to more miscarriages. For this reason, the hysteroscopic morcellator was replaced with the 21 Fr. Princess Bipolar Resectoscope (see image 2). Using the bipolar loop in normal saline, the pseudocapsule of the intramural portion of myoma was identified, the myoma was massaged into the uterine cavity with blunt dissection and 100% of the myoma was removed. The total saline fluid deficit was 760 mls.

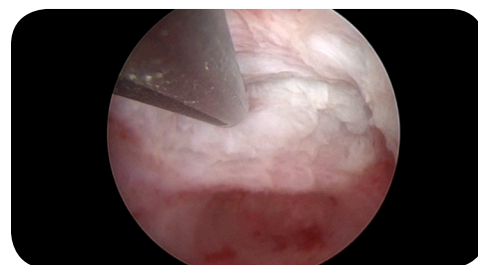


Image 1

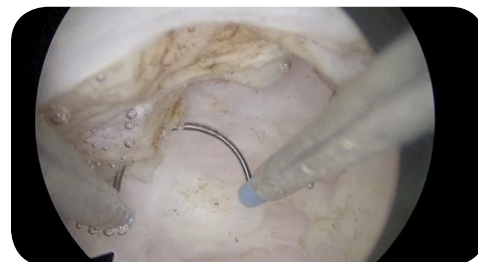

Image 2

Use of the 21 Fr. Princess Bipolar Resectoscope for Hysteroscopic Resection of Submucosal Fibroids

Techniques by DR. KEITH ISAACSON


Patient's periods returned to normal after two cycles. She is currently in her second trimester of a normal pregnancy.

Discussion

The take home message from this report is twofold. The first is that the goal of a hysteroscopic myomectomy is to remove 100% of a submucous myoma. By definition, partial myomectomies leave viable tissue within the myometrium. This tissue has the potential to grow and remain symptomatic. The current design of the intrauterine morcellators does not allow for the removal of the intramural portions of Type I and Type II submucous myomas. The second message is understanding the technique for removing the intramural portion of a submucous myoma with a resectoscope. Fibroids that are not adenomyotic displace the myometrium and do not invade the myometrium. If the pseudocapsule can be identified, there is no reason to cut any myometrium. If the surgeon does not cut the myometrium, there is minimal risk of uterine perforation. The only reason not to complete a surgery is due to saline intravasation which, according to the revised AAGL guidelines, should be capped at 2500 mls.

Likewise the surgeon should be aware of the costs of all disposable items used within a surgical case. Presently, the cost of the disposable morcellator equipment is nearly 5 times higher than the bipolar disposable loop.

Like most new technologies, surgeon training is key to optimizing the patient's outcome. Hysteroscopic resection has a short learning curve and should not be perceived as a needing extensive training to achieve the best result for the patient.



DR. KEITH ISAACSON, MD

Dr. Isaacson currently serves as the Associate Professor of Ob/Gyn at Harvard Medical School and the Director of Partners Center for Reproductive Medicine and Surgery at Newton Wellesley Hospital MIGS Center. Dr. Isaacson was President of AAGL 2011–2012.



spirit of excellence

353 Corporate Woods Parkway, Vernon Hills, IL 60061

For more information, contact your local sales representative,
or call (800) 323-WOLF (9653)

www.richardwolfusa.com